

Research Paper

Morphoanatomy of the Mandibular Foramen and Clinical Implications: Linear and Triangular Measurements in West Bengal

Santanu Bhattacharya¹ , Moumita Saha^{2*}

1. Department of Anatomy, Burdwan Medical College and Hospital, PurbaBardhaman, India.

2. Department of Anatomy, Jalpaiguri Government Medical College and Hospital, Jalpaiguri, India.



Citation Bhattacharya S, Saha M. Morphoanatomy of the Mandibular Foramen and Clinical Implications: Linear and Triangular Measurements in West Bengal. *Anatomical Sciences*. 2024; 21(1):31-42. <https://doi.org/10.32598/ASJ.20.3.440.1>

<https://doi.org/10.32598/ASJ.20.3.440.1>

Article info:**Received:** 15 Jun 2023**Accepted:** 02 Jul 2023**Available Online:** 01 Jan 2024**ABSTRACT**

Introduction: The mandibular foramen, located on the medial surface of the mandibular ramus, is a crucial anatomical landmark for delivering local anesthesia during dental procedures. Accurate localization of this foramen is critical for successful inferior alveolar nerve block administration. However, the conventional approach to this nerve block often relies on blind techniques, which are associated with a high failure rate and potential complications. This study aimed to enhance the precision of locating the mandibular foramen by evaluating two different methods to improve the effectiveness of nerve blocks.

Methods: This study was conducted using a sample size of sixty-three mandibles, wherein the precise position of the mandibular foramen was analysed using two separate localization techniques: 1) the linear measurement method, which determines distances from the foramen to key anatomical landmarks, such as the mandibular notch, posterior border of the ramus, angle of the mandible, base of the mandible, and anterior border of the ramus; and 2) the triangular measurement method, which utilizes three reference points—midpoint of the anterior border of the mandibular ramus, the socket for the third molar tooth, and their distance from the mandibular foramen—to create a triangular framework for foramen localization. The efficacy of each method was assessed based on its accuracy and clinical applicability.

Results: The study assessed the precise anatomical location of the mandibular foramen using two different methods. No statistically significant differences were found between the right and left sides for any measured parameters, including distances from the mandibular foramen to various anatomical landmarks. Both methods were valuable, with the first providing more comprehensive data through multiple measurements, while the second offered simplicity and ease of clinical application. Although the first method was more detailed, the second may be more practical in clinical settings.

Conclusion: Precise localization of the mandibular foramen is essential for the effective administration of inferior alveolar nerve blocks. This study highlights the importance of adopting accurate methods for foramen identification, as doing so can significantly improve the success rate of dental anesthesia and reduce the risk of complications.

Keywords:

Mandibular foramen, Inferior alveolar nerve block, Dental anesthesia

*** Corresponding Author:**

Moumita Saha, Assistant Professor.

Address: Department of Anatomy, Jalpaiguri Government Medical College and Hospital, Jalpaiguri, India.

Tel: +91 (912) 3854189

E-mail: moumitanrsmch@gmail.com

Copyright © 2024 The Author(s);

This is an open access article distributed under the terms of the Creative Commons Attribution License (CC-BY-NC: <https://creativecommons.org/licenses/by-nc/4.0/legalcode.en>), which permits use, distribution, and reproduction in any medium, provided the original work is properly cited and is not used for commercial purposes.

Introduction

The mandibular foramen is located on the medial surface of the ramus of the mandible, roughly midway between the mandibular notch and the angle of the mandible [1]. This foramen is an opening that leads to a canal, which curves downward and forward into the body of the mandible until it reaches the mental foramen. Through this canal, the inferior alveolar nerve and vessels pass, making its precise location critical for effective anesthesia administration during dental procedures [2]. The position of the mandibular foramen serves as a vital anatomical landmark for achieving successful anesthesia of the inferior alveolar nerve, which is essential for dental extractions and pain management [3].

This study aimed to determine the exact position of the inferior alveolar nerve using two different methods, and to identify which method is more convenient, adding novelty to our research. The mandibular foramen is crucial for administering local anesthesia in the lower jaw. The inferior alveolar nerve, which carries sensation from the lower teeth and gums, passes through this foramen. Anesthetizing this nerve is essential for ensuring pain control during dental procedures such as extractions, root canals, and other surgical interventions in the lower jaw [4]. Therefore, identifying the mandibular foramen accurately is of utmost importance in dental anesthesia management [5].

The conventional inferior alveolar nerve block is commonly performed near the mandibular foramen. This technique is widely used to achieve anesthesia for procedures involving the mandibular teeth. Despite its widespread use, this method often involves a blind approach based on anticipated anatomical landmarks, leading to a high failure rate and potential complications, such as aspiration and inadvertent nerve injury [6]. Enhancing the success rate and minimizing complications necessitates precise identification of the foramen [7].

The mandibular foramen opens into the mandibular canal, a bony channel that extends downward and forward within the mandible. This canal contains the inferior alveolar nerve and blood vessels, which supply the lower teeth, gums, and other structures in the region [8]. Accurate localization of the mandibular foramen is also crucial for oral surgeons when performing surgical procedures in the lower jaw, such as wisdom tooth extraction or implant placement. Precise identification helps prevent inadvertent nerve injury, which can result in complications, such as numbness or paresthesia in the

lower lip, chin, and tongue [9]. Identifying the mandibular foramen on dental radiographs (X-rays) is vital for diagnosing and planning treatments for various dental and oral conditions [10]. Understanding the anatomical landmarks of the mandibular foramen is fundamental for dental students and practitioners. It contributes to their knowledge of oral and maxillofacial anatomy, aiding in accurate treatment planning and patient care [11].

This study aimed to provide valuable insights into the anatomical and morphological characteristics of the mandibular foramen, and to enhance clinical practices in dental anesthesia and surgical procedures. By identifying different landmarks that help accurately locate the mandibular foramen using two measurement methods, we aim to improve clinical practices, ultimately benefiting patient care and minimizing potential complications [12, 13]. Accurate identification of the mandibular foramen is vital to enhance the success rate of inferior alveolar nerve blocks and minimize complications [14]. Despite being performed based on anticipated anatomical landmarks, the conventional intraoral approach to this nerve block often has a high failure rate and potential complications, such as nerve injury and aspiration. Therefore, precise localization of the mandibular foramen is imperative for dental anesthesia, surgical procedures, and radiographic interpretations [15]. This knowledge significantly contributes to dental students' and practitioners' understanding of oral and maxillofacial anatomy

Materials and Methods

This study was designed as an observational cross-sectional study, conducted over six months at [Jalpaiguri Government Medical College \(JGMCH\)](#) in the Department of Anatomy. The study employed convenient sampling, utilizing available mandibles from the Department of Anatomy at [JGMCH](#). Total sixty three mandibles were collected from the Department of Anatomy, [JGMCH](#). The exclusion criteria were applied to omit deformed and damaged bones to ensure accuracy in measurements. All measurements were performed by Vernier callipers.

Measurement methods

1) Linear measurement method: ([Figure 1](#)):

1. Superior border of mandibular foramen (MF) to the mandibular notch (MN) (MF-MN);
2. Posterior border of MF to the posterior border of ramus (MF-PBR);
3. Posteroinferior border of MF to the angle of mandible (MF-ANGLE);
4. Inferior border of MF to the base of mandible (MF-BASE);

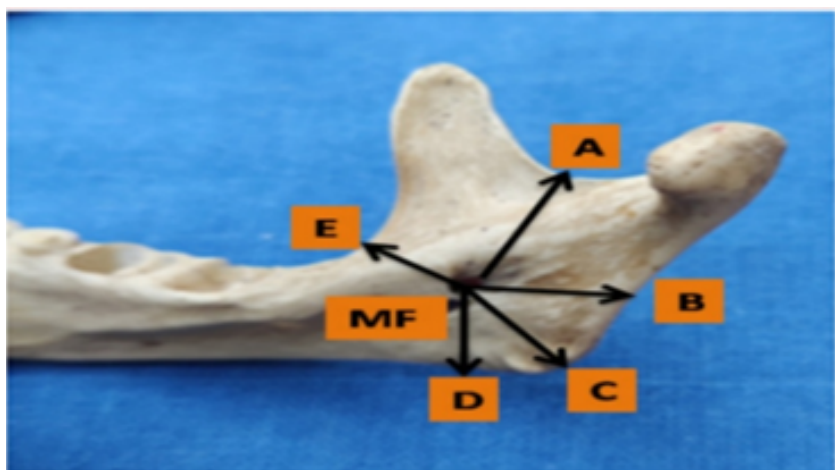


Figure 1. Linear measurement method

Abbreviation: MF: Mandibular foramen; A: Mandibular notch; B: Posterior border; C: Angle of mandible; D: Base of mandible; E: Anterior of border.

ANATOMICAL SCIENCES

2) Triangular measurement method (Figure 2):

1. distance from MF to midpoint of the anterior border of mandibular ramus (MF to 1); 2. distance from MF to socket for 3rd molar tooth (MF to 2); 3. distance from first and second point.

These three measurements form a triangle, aiding in the precise localization of the inferior alveolar nerve. The recorded measurements were tabulated and analyzed using Epi-info software, version 7.2.6.0. Descriptive statistics, including minimum, maximum, Mean \pm SD, were calculated for all parameters.

Results

The study aimed to determine the precise anatomical location of the MF using two different measurement methods on both the right and left sides of the mandible. The Tables 1, 2, 3, 4, 5, 6 and 7 present the summarized data for each parameter, including the measurements from the superior border of the mandibular foramen to the mandibular notch (MF-MN), posterior border of the mandibular foramen to the MF-PBR, posteroinferior border of the mandibular foramen to the angle of the mandible (MF-ANGLE), inferior border of the mandibular foramen to the base of the mandible (MF-BASE), and anterior border of the mandibular foramen to the anterior border of the ramus (MF-ABR).

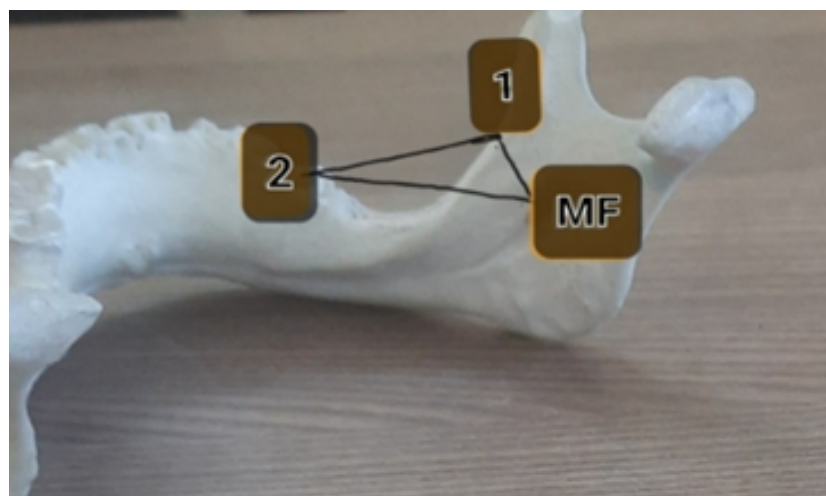


Figure 2. Triangular measurement method

ANATOMICAL SCIENCES

Table 1. Descriptive statistics for MF-BASE by side (unit of measurement in mm) (n=63)

Variables	Mean±SD	Variance	Min	25 th (%)	Median	75 th (%)	Max	Mode
Right side	24.5±4.78	22.88	13.5	21.0	24.8	28.3	32.0	18.9
Left side	25.07±4.51	20.36	15.1	21.7	26.2	28.5	32.0	26.2

ANOVA for MF-BASE by Side					
Source	SS	df	MS	F Statistic	P
Between	10.22865	1	10.22865	0.47312	0.49284
Within	2680.85270	124	21.61978		
Total	2691.08135	125			

Bartlett's Test for MF-BASE by Side		
Bartlett's Chi Square	df	P
0.20987	1	0.64687

Mann-Whitney/Wilcoxon Two-sample Test for MF-BASE by Side	
Statistic	Value
Kruskal-Wallis H	0.4404
Degrees of freedom	1
P	0.5069

ANATOMICAL SCIENCES

These tables organize and present the statistical analysis results for each measurement by side (right and left) and include descriptive statistics, t-tests, ANOVA, Bartlett's test, and Mann-Whitney/Wilcoxon tests.

MF-BASE

The mean measurement on the right side was 24.5 mm with a standard deviation of 4.78 mm, and the median was 24.8 mm. Measurements ranged from 13.5 mm to 32.0 mm. On the left side, the Mean±SD was slightly higher at 25.07±4.51 mm, and the median was 26.2 mm, with measurements ranging from 15.1 mm to 32.0 mm. The t-test for the difference between the means showed no statistically significant difference, with a P=0.4928, indicating that the side (right or left) does not significantly affect the mean measurement (Table 1).

MF-3rd molar

The Mean±SD measurement for the right side was 19.14±5.14 mm, and the median was 19.7 mm, ranging from 8.4 mm to 29.9 mm. For the left side, the mean was 19.47±4.82 mm, and the median was 19.9 mm, with a range of 8.0 mm to 28.2 mm. The t-test results also showed no significant difference between the sides, with a P=0.7120 (Table 2).

MF-ABR

For the right side, the mean measurement was 16.15±2.60 mm, and the median was 16.8 mm, ranging from 10.1 mm to 21.7 mm. The left side had a mean of 16.53±3.05 mm, and the median was 16.7 mm, with a range of 10.6 mm to 24.7 mm. The t-test indicated no significant difference between the two sides, with a P=0.4504 (Table 3).

MF-MN

The mean measurement on the right side was 17.73±3.23 mm, and the median was 16.7 mm, ranging from 12.8 mm to 26.7 mm. On the left side, the mean was 17.58±3.03 mm, and the median was 17.4 mm, with a range of 12.2 mm to 26.1 mm. The t-test for this comparison also showed no significant difference, with a P=0.7919 (Table 4).

Table 2. Descriptive statistics for MF-3rd molar by side (n=63) (unit of measurement in mm)

Variables	Mean±SD	Variance	Min	25 th (%)	Median	75 th (%)	Max	Mode
Right side	19.14±5.14	26.40	8.4	15.8	19.7	22.0	29.9	8.4
Left side	19.47±4.82	23.26	8.0	15.8	19.9	22.3	28.2	15.5

ANOVA for MF-3 rd Molar by Side					
Source	SS	df	MS	F statistic	P
Between	3.40071	1	3.40071	0.13695	0.71196
Within	3079.10286	124	24.83147		
Total	3082.50357	125			

Bartlett's Test for MF-3 rd Molar by Side		
Bartlett's Chi Square	df	P
0.24739	1	0.61892

Mann-Whitney/Wilcoxon Two-sample Test for MF-3 rd Molar by Side	
Statistic	Value
Kruskal-Wallis H	0.0607
Degrees of freedom	1
P	0.8053

ANATOMICAL SCIENCES

These tables organize and present the statistical analysis results for each measurement by side (right and left) and include descriptive statistics, t-tests, ANOVA, Bartlett's test, and Mann-Whitney/Wilcoxon tests.

MF-PBR

The right side had a mean measurement of 11.33±2.21 mm, and the median was 11.6 mm, with measurements ranging from 5.9 mm to 15.7 mm. The left side had a mean of 11.32±2.06 mm, and the median was 11.1 mm, with a range of 7.5 mm to 15.8 mm. The t-test results showed no significant difference between the sides, with a P=0.9701 (Table 5).

MF-angle of the mandible (ANGLE)

The mean measurement on the right side was 21.68±3.71 mm, and the median was 21.4 mm, ranging from 13.9 mm to 27.9 mm. The left side had a mean of 22.00±4.12 mm, and the median was 21.7 mm, with a range of 12.6 mm to 30.3 mm. The t-test indicated no significant difference, with a P=0.6393 (Table 6).

(MF-ABR) to (MF-3rd molar)

For the right side, the mean was 4.40±3.23 mm, and the median was 3.8 mm, ranging from 0.1 mm to 12.1 mm. The left side had a mean of 4.77±3.4 mm, and the median was 4.0 mm, with a range of 0.2 mm to 11.0 mm. The t-test showed no significant difference, with a P=0.5306 (Table 7). Overall, no statistically significant differences were found between the right and left sides for any of the measured variables. This suggests that the measurements are consistent and symmetrical between the sides.

Comparison of two methods

The first method involves more measurements directly related to anatomical landmarks, which could potentially provide more detailed and consistent results. The second method is less complex but may lack the detailed spatial orientation provided by the first method. The second method might be more straightforward to apply clinically.

Table 3. Descriptive statistics for MF-ABR by side (n=63) (Unit of measurement in mm)

Variables	Mean±SD	Variance	Min	25 th (%)	Median	75 th (%)	Max	Mode
Right side	16.15±2.60	6.78	10.1	14.2	16.8	17.8	21.7	16.2
Left side	16.53±3.05	9.31	10.6	14.0	16.7	19.0	24.7	16.7

ANOVA for MF-ABR by Side					
Source	SS	df	MS	F statistic	P
Between	4.60960	1	4.60960	0.57317	0.45044
Within	997.24508	124	8.04230		
Total	1001.85468	125			

Bartlett's Test for MF-ABR by Side		
Bartlett's Chi Square	df	P
1.53589	1	0.21523

Mann-Whitney/Wilcoxon Two-sample Test for MF-ABR by Side	
Statistic	Value
Kruskal-Wallis H	0.7588
Degrees of freedom	1
P	0.3837

ANATOMICAL SCIENCES

These tables organize and present the statistical analysis results for each measurement by side (right and left) and include descriptive statistics, t-tests, ANOVA, Bartlett's test, and Mann-Whitney/Wilcoxon tests.

cally because it involves fewer steps and measurements. However, the first method's multiple parameters might offer more comprehensive data, making it more reliable despite its complexity.

Based on the detailed and comprehensive nature of the first method, it seems to provide a more thorough approach to identifying the exact anatomical location of the mandibular foramen. Although it involves more steps, the detailed measurements from various landmarks likely enhance the accuracy and reliability of the location. However, if ease and speed of application are critical, the second method could be more convenient in clinical practice. Further study is needed to draw a more definitive conclusion. Both methods, when used appropriately, contribute valuable insights for dental anesthesia and surgical procedures.

Discussion

The mandible, the largest and strongest bone of the face, plays a vital role in multiple functions, including mastication, speech, and facial expression. Its anatomy,

particularly the mandibular foramen, is crucial for various clinical procedures, especially in dental and maxillofacial surgery. Mandible forms the lower jaw and the only movable bone of the skull. This discussion integrates findings from multiple studies to offer a detailed understanding of the morphometric characteristics of the mandibular foramen and its clinical relevance.

Saify et al. (2023) conducted a detailed morphometric study of the mandibular foramen, finding it located at an average distance of 18.1±2.4 mm from the anterior border of the ramus. This information is crucial for clinicians performing inferior alveolar nerve blocks, as accurate knowledge of the foramen's position facilitates effective anesthesia administration [2]. This finding corroborates the study by Kilarkaje et al. (2005), which observed that the mandibular foramen maintains bilateral symmetry across different age groups. This consistency in anatomical landmarks is significant for surgical planning and ensures predictable outcomes in different populations [3].

Table 4. Descriptive Statistics for MF-MN by Side (N=63) (Unit of measurement in mm)

Variables	Mean±SD	Variance	Min	25 th (%)	Median	75 th (%)	Max	Mode
Right side	17.73±3.23	10.46	12.8	15.7	16.7	19.4	26.7	16.6
Left side	17.58±3.03	9.17	12.2	15.4	17.4	19.0	26.1	17.4

ANOVA for MF-MN by Side					
Source	SS	df	MS	F statistic	P
Between	0.86470	1	0.86470	0.07010	0.79192
Within	1530.5790	124	12.3434		
Total	1531.4438	125			

Bartlett's Test for MF-MN by Side		
Bartlett's Chi Square	df	P
0.15821	1	0.69099

Mann-Whitney/Wilcoxon Two-sample Test for MF-MN by Side	
Statistic	Value
Kruskal-Wallis H	0.0462
Degrees of freedom	1
P	0.8298

ANATOMICAL SCIENCES

These tables organize and present the statistical analysis results for each measurement by side (right and left) and include descriptive statistics, t-tests, ANOVA, Bartlett's test, and Mann-Whitney/Wilcoxon tests.

Further research has explored the variability in the mandibular foramen's location across various populations. Gupta et al. (2021) highlighted the variability in the foramen's position and its implications for dental anesthesia, emphasizing the importance of anatomical knowledge tailored to specific populations [4]. This variability underscores the necessity for region-specific studies to improve the effectiveness of dental procedures, especially in areas with diverse demographic profiles.

In a study focused on the Thai population, Thunyacharoen et al. (2020) examined not only the location of the mandibular foramen but also the prevalence of accessory mandibular foramina. Their findings revealed differences among ethnic groups, indicating that anatomical variations can influence clinical outcomes and the approach to mandibular procedures [5]. Such studies are pivotal in developing region-specific protocols and enhancing the precision of medical and dental interventions.

The relationship between mandibular morphology and functional aspects, such as masticatory muscle force, has been explored by Sella Tunis et al. (2018), who found that the shape of the mandible is significantly correlated with masticatory muscle strength. This suggests that variations in mandibular structure may impact its functional performance, which could, in turn, influence the position and structure of the mandibular foramen [6]. Similarly, Simone et al. (2018) investigated how food hardness affects mandibular development and muscle coordination in infants and young children. Their study indicated that dietary factors might lead to structural differences in the mandible, potentially affecting the location of the mandibular foramen across different populations [7].

Selukar et al. (2020) provided valuable insights into the anatomical distances between the mandibular foramen and other key landmarks, which are essential for accurate surgical planning. Their study highlights the importance of detailed anatomical knowledge for minimizing complications during mandibular procedures [8]. Com-

Table 5. Descriptive statistics for MF-PBR by side (n=63) (unit of measurement in mm)

Variables	Mean±SD	Variance	Min	25 th (%)	Median	75 th (%)	Max	Mode
Right side	11.33±2.21	4.88	5.9	9.5	11.6	12.9	15.7	15.0
Left side	11.32±2.06	4.23	7.5	9.7	11.1	12.7	15.8	11.0

ANOVA for MF-PBR by Side					
Source	SS	df	MS	F statistic	P
Between	0.00785	1	0.00785	0.00103	0.97006
Within	941.00552	124	7.58956		
Total	941.01337	125			

Bartlett's Test for MF-PBR by Side		
Bartlett's chi square	df	P
0.73292	1	0.39210

Mann-Whitney/Wilcoxon Two-sample Test for MF-PBR by Side	
Statistic	Value
Kruskal-Wallis H	0.0052
Degrees of freedom	1
P	0.9424

ANATOMICAL SCIENCES

These tables organize and present the statistical analysis results for each measurement by side (right and left) and include descriptive statistics, t-tests, ANOVA, Bartlett's test, and Mann-Whitney/Wilcoxon tests.

plementing this, Sultana et al. (2019) conducted a study in Southern India, while Muche et al. (2019) focused on Switzerland, both contributing to our understanding of the bilateral symmetry of the mandibular foramen's position [9, 10]. Gopalakrishna et al. (2016) also confirmed the bilateral symmetry of the mandibular foramen's position, reinforcing the consistency observed in various studies [11].

The study by Amjad et al. (2018) on Maharashtra mandibles provided data on the average width of the mandibular ramus, with measurements of 30.23 mm on the right side and 30.02 mm on the left side. This finding aligns with the research by Patil et al. (2015), which also reported similar dimensions, emphasizing the consistency in mandibular ramus measurements across different studies [12, 13]. Prado et al. (2010) investigated Brazilian subjects and found that the position of the mandibular foramen relative to the anterior and posterior borders of the ramus is similar on both sides, a finding also supported by Sastya et al. (2016) [14, 15]. These studies

highlight the bilateral symmetry of the mandibular foramen, which is crucial for developing standardized clinical practices.

Ennes et al. (2009) observed that the most frequent location of the mandibular foramen is in the mean third of the mandibular ramus, both in anteroposterior and superoinferior directions. This finding helps in establishing a standardized anatomical reference for clinical applications, ensuring more accurate and predictable outcomes in mandibular-related procedures [15].

Shah et al. [16] studied 100 human mandibles from Ahmadabad and found the average distance of mandibular foramen was 23-25 mm from mandibular notch (it was average 17.73 mm on right side and 17.58 average mm on left side), 16-18 mm from anterior border of ramus (it was 16.15 mm on right side and 16.53 mm on left side), which is quite similar with the study.

Table 6. Descriptive statistics for MF-ANGLE by side (n=63) (unit of measurement in mm)

Variables	Mean±SD	Variance	Min	25 th (%)	Median	75 th (%)	Max	Mode
Right side	21.68±3.71	13.74	13.9	19.2	21.4	23.7	27.9	21.4
Left side	22.00±4.12	16.96	12.6	19.6	21.7	24.8	30.3	15.0

ANOVA for MF-ANGLE by Side					
Source	SS	df	MS	F statistic	P
Between	3.02990	1	3.02990	0.22114	0.63927
Within	1698.1615	124	13.6926		
Total	1701.1914	125			

Bartlett's Test for MF-ANGLE by Side		
Bartlett's Chi Square	df	P
1.04507	1	0.30659

Mann-Whitney/Wilcoxon Two-Sample Test for MF-ANGLE by Side	
Statistic	Value
7Kruskal-Wallis H	0.3143
Degrees of freedom	1
P	0.5752

ANATOMICAL SCIENCES

These tables organize and present the statistical analysis results for each measurement by side (right and left) and include descriptive statistics, t-tests, ANOVA, Bartlett's test, and Mann-Whitney/Wilcoxon tests.

According to study conducted by Oguz et al. [17] on west Indian mandibles, the mandibular foramen was positioned at 16.09 mm on right side and 16.78 mm on left side from anterior border of mandibular ramus, whereas in our study, it was 16.15 mm in right side and 16.53mm on left side.

The second method, which features a triangle designed by the authors, is highly practical and straightforward, making it an invaluable tool for clinicians, especially in situations where efficiency and simplicity are crucial. Although it may not yield the detailed data offered by the first method, its clinical usefulness lies in providing sufficiently accurate results with minimal complexity. This makes it an ideal option for routine dental anesthesia and surgical procedures.

Conclusion

In conclusion, the morphometric study of the mandibular foramen reveals crucial insights into its anatomical variability and clinical significance. The consistency in

bilateral symmetry and average dimensions across different studies supports its clinical utility, while the observed variability across populations underscores the need for localized anatomical assessments. These findings are crucial for enhancing surgical precision and optimizing patient outcomes in mandibular-related procedures. Future research should continue to explore these variations to further refine clinical practices and improve the effectiveness of interventions involving the mandible.

Ethical Considerations

Compliance with ethical guidelines

The study was approved by the Ethics Committee of JGMCH, Jalpaiguri, India (Code:JGMC&H/17).

Funding

This research did not receive any grant from funding agencies in the public, commercial, or non-profit sectors.

Table 7. Descriptive statistics for (MF-ABR) to (MF-3rd Molar) by side (n=63) (unit of measurement in mm)

Variables	Mean±SD	Variance	Min	25 th (%)	Median	75 th (%)	Max	Mode
Right side	4.40±3.23	10.46	0.1	1.6	3.8	6.4	12.1	4.0
Left side	4.77±3.42	11.69	0.2	1.8	4.0	6.8	11.0	4.0

ANOVA for (MF-ABR) to (MF-3rd Molar) by Side					
Source	SS	df	MS	F statistic	P
Between	3.73995	1	3.73995	0.39599	0.53062
Within	1170.2994	124	9.4395		
Total	1174.0394	125			

Bartlett's Test for (MF-ABR) to (MF-3rd Molar) by Side		
Bartlett's Chi Square	df	P
0.21494	1	0.64288

Mann-Whitney/Wilcoxon Two-Sample Test for (MF-ABR) to (MF-3rd Molar) by Side	
Statistic	Value
Kruskal-Wallis H	0.3950
Degrees of freedom	1
P	0.5297

These tables organize and present the statistical analysis results for each measurement by side (right and left) and include descriptive statistics, t-tests, ANOVA, Bartlett's test, and Mann-Whitney/Wilcoxon tests.

Authors' contributions

All authors contributed equally to the conception and design of the study, data collection and analysis, interpretation of the results, and drafting of the manuscript. Each author approved the final version of the manuscript for submission.

Conflict of interest

The authors declared no conflict of interest.

Acknowledgments

The authors express their gratitude to the Head of the Department and the other faculty members of the Department of Anatomy of JGMCH, Jalpaiguri.

References

- [1] Datta AK, editor. Human anatomy, head and neck. 5th ed. India: Current Book International; 2009.
- [2] Saify SI, Fatima K, Shahdad S, Bhat GM. Morphometric study of mandibular foramen and its clinical significance in inferior alveolar nerve block. *International Journal of Research in Medical Sciences*. 2023; 11(5):1600-4. [DOI:10.18203/2320-6012.ijrms20231322]
- [3] Kilarkaje N, Nayak SR, Narayan P, Prabhu LV. The location of the mandibular foramen maintains absolute bilateral symmetry in mandibles of different age-groups. *Hong Kong Journal of Dental Research*. 2005; 2(1):35-7. [Link]
- [4] Gupta AK, Shah GJ, Prasad RJ. Study of mandibular foramen in adult human mandible bones: An osteological study. *Journal of Nepalgunj Medical College*. 2021; 19(1):18-21. [DOI:10.3126/jngmc.v19i1.40047]
- [5] Thunyacharoen S, Lymkhanakhom S, Chantakhat P, Suwanin S, Sawanprom S, Iamaroon A, et al. An Anatomical study on locations of the mandibular foramen and the accessory mandibular foramen in the mandible and their clinical implications in a Thai Population. *Anatomy and cell Biology* 2020; 53(3):252-60. [DOI:10.5115/acb.20.079] [PMID]

- [6] Sella Tunis T, Pokhojaev A, Sarig R, O'Higgins P, May H. Human mandibular shape is associated with masticatory muscle force. *Scientific Reports*. 2018; 8(1):6042. [DOI:10.1038/s41598-018-24293-3] [PMID]
- [7] Simione M et al. Differing structural properties of foods affect the development of mandibular control and muscle coordination in infants and young children. *Physiology & Behavior*. 2018; 186:62-72. [DOI:10.1016/j.physbeh.2018.01.009] [PMID]
- [8] Selukar MS, Sudke GB. Anatomical study of mandibular foramen in dry adult human mandibles. *Medpulse*. 2020; 16(1):06-09. [DOI:10.26611/10011612]
- [9] Sultana Z, Sreekanth T. A morphometric study of mandibular foramen in dry adult human mandibles of Indian population in Telangana State. *International Journal of Anatomy and Research*. 2019; 7(4.2):7080-85. [DOI:10.16965/ijar.2019.308]
- [10] Muche A, Saniotis A. Position of mandibular foramen and its clinical implications. *Italian Journal of Anatomy and Embryology*. 2019; 124(3):319-28. [DOI:10.13128/ijae-11660]
- [11] Gopalakrishna K, Deepalaxmi S, Somashekara SC, Ratna BS. An Anatomical study on the position of mandibular foramen in 100 dry mandibles. *Int J Anat Res*. 2016; 4:1967-71.
- [12] Amjad S, Zuberi HR, Ahmed AS. Study of mandibular foramen from different bony landmarks in dry human mandibles. *Indian Journal of Anatomy & Surgery of Head Neck and Brain*. 2018; 4(2):40-3. [DOI:10.18231/2581-5229.2018.0011]
- [13] Patil K, Guledgud MV, Bhattacharya PT. Reliability of panoramic radiographs in the localization of mandibular Foramen. *Journal of Clinical and Diagnostic Research*. 2015; 9(5):ZC35-8. [DOI:10.7860/JCDR/2015/11641.5893] [PMID]
- [14] Prado FB, Groppo FC, Volpato MC, Caria, PHF. Morphological changes in the position of the mandibular foramen in dentate and edentate Brazilian subjects. *Clinical Anatomy*. 2016; 5(10):62-64. [DOI:10.1002/ca.20973] [PMID]
- [15] Ennes JP, Medeiros RM. Localization of mandibular foramen and clinical implications. *Int J Morphol*. 2009; 27(4):1305-11. [Link]
- [16] Shah K, Shah P, Parmar A. Study of the location of mandibular foramina in Indian dry mandibles. *Global Research Analysis*. 2013; 2(7):128-30. [Link]
- [17] Oguz O, Bozkir MG. Evaluation of location of mandibular and mental foramina in dry, young, adult human male, dentulous mandibles. *The West Indian Medical Journal*. 2002; 51(1):14-6. [PMID]

This Page Intentionally Left Blank